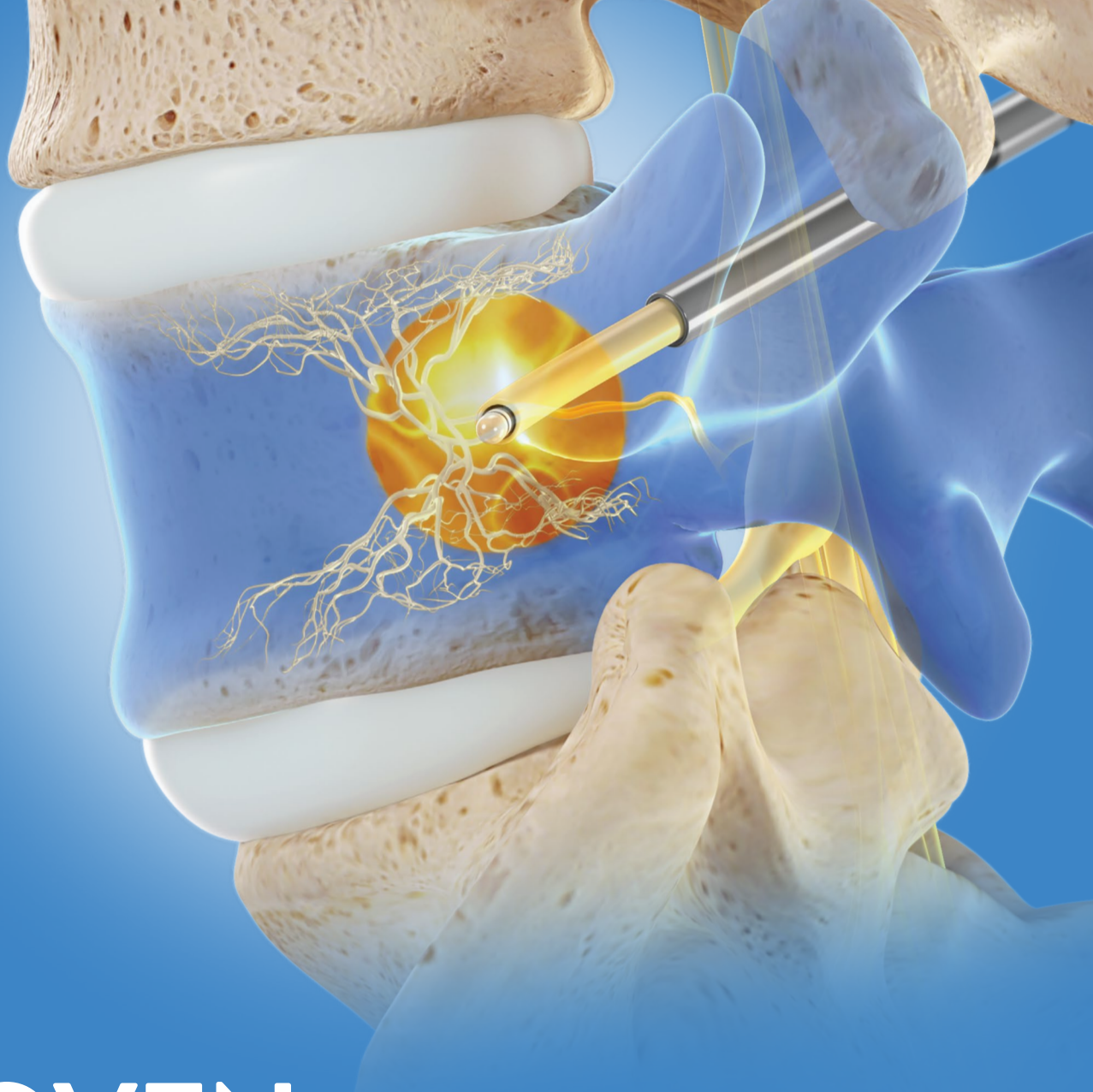



PROVEN, DURABLE RELIEF

The Intracept[®] Procedure

FOR CHRONIC VERTEBROGENIC LOW BACK PAIN

relievant
medsystems

Vertebral Endplates

are a Significant Source of Chronic Low Back Pain

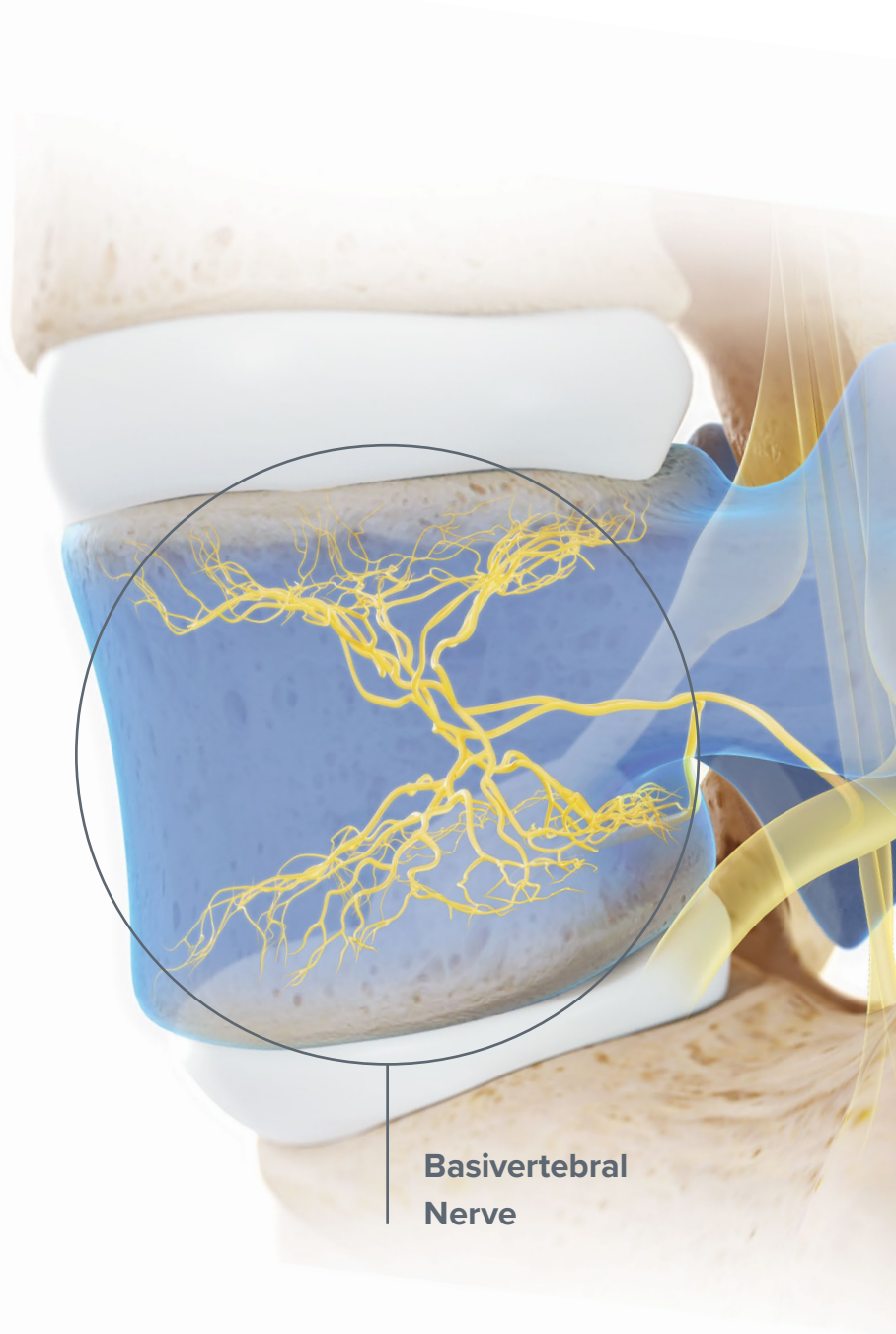
Research Findings

1 Vertebral endplates are more innervated than intervertebral discs¹

2 The basivertebral nerve innervates the endplates and proliferates in damaged and degenerated endplates^{2,3}

3 Modic changes and associated endplate damage strongly correlate with chronic low back pain^{4,5,6,7,8}

Collectively, these findings validate vertebral endplates as a significant source of chronic low back pain in patients with Type 1 or Type 2 modic changes, also referred to as vertebrogenic pain, and this pain is transmitted via the basivertebral nerve.



The Intracept Procedure

for the Relief of Chronic Vertebrogenic Low Back Pain

The **Intracept Procedure** is a minimally invasive procedure that targets the basivertebral nerve for the relief of chronic vertebrogenic low back pain.

Key Benefits of Intracept

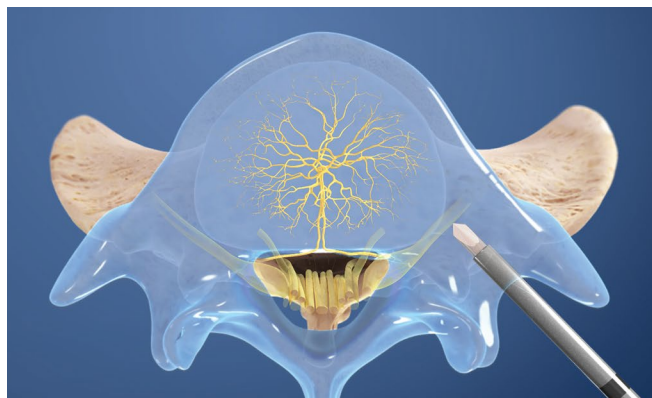
- **Provides a treatment option for patients who have not responded to conservative therapy**
- **Minimally invasive, outpatient procedure**
- **Implant-free and preserves the structure of the spine**
- **Provides durable relief of chronic vertebrogenic low back pain⁹**

Indications and Risks

The Intracept Intraosseous Nerve Ablation System is intended to be used in conjunction with radiofrequency (RF) generators for the ablation of basivertebral nerves of the L3 through S1 vertebrae for the relief of chronic low back pain of at least six months duration that has not responded to at least six months of conservative care, and is also accompanied by features consistent with Type 1 or Type 2 Modic changes on an MRI such as inflammation, edema, vertebral endplate changes, disruption and fissuring of the endplate, vascularized fibrous tissues within the adjacent marrow, hypointensive signals (Type 1 Modic change), and changes to the vertebral body marrow including replacement of normal bone marrow by fat, and hyperintensive signals (Type 2 Modic change).

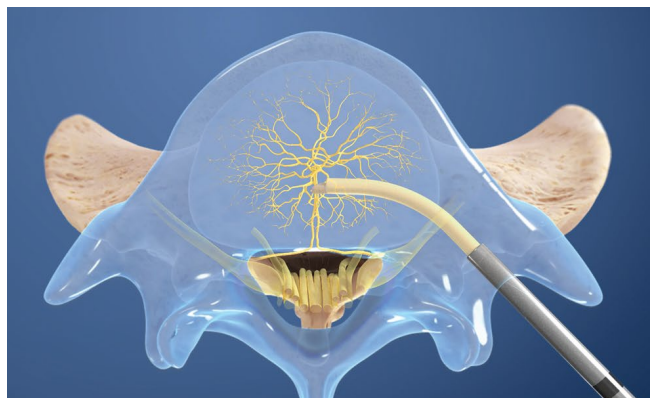
As with any surgical procedure, there are risks and considerations associated with the Intracept Procedure. Please see the device labeling for a discussion of the risks, contraindications, warnings and precautions.

Intrasept Procedure Steps



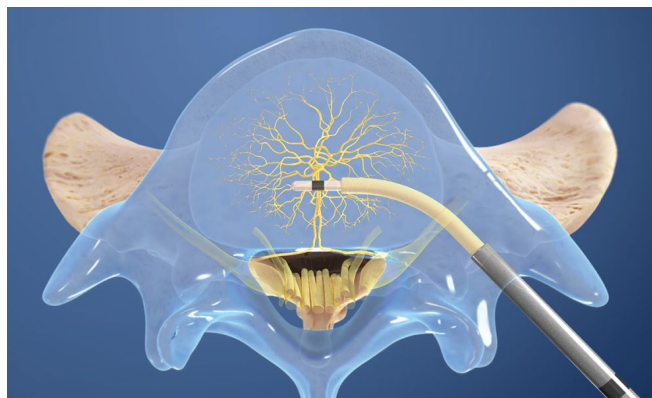
1 Access the pedicle

Under fluoroscopic guidance, the Intrasept Introducer Cannula is advanced through the pedicle



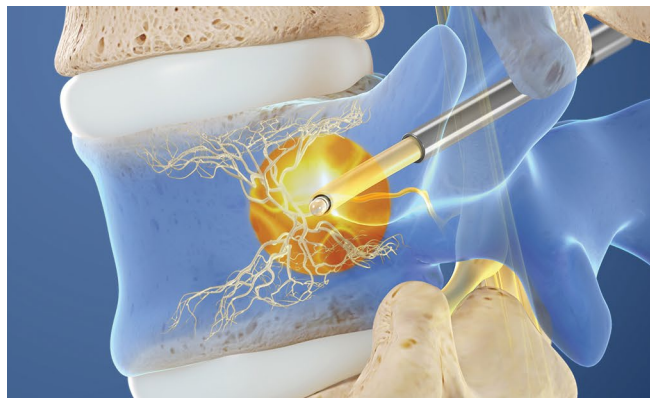
2 Create the channel

The Intrasept Curved Cannula is utilized to create a channel to the trunk of the basivertebral nerve



3 Place the RF Probe

The Intrasept Radiofrequency Probe is inserted into the curved path and placed at the basivertebral nerve



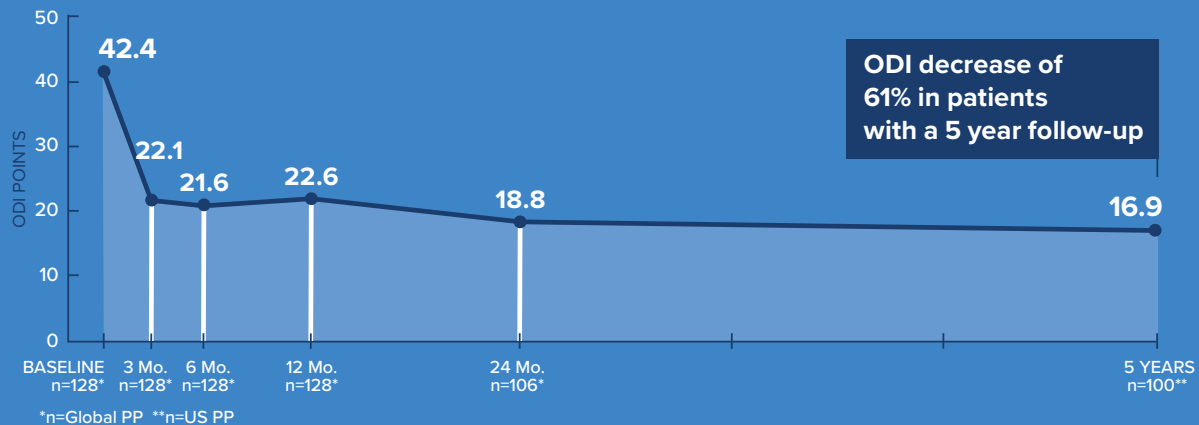
4 Ablate the BVN

The Reliant Radiofrequency Generator is utilized to ablate the basivertebral nerve

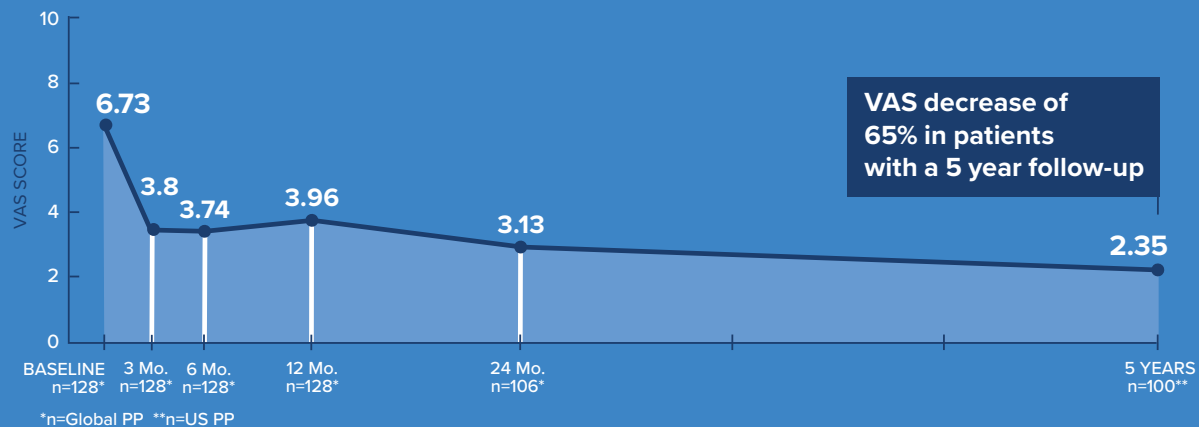
UNPARALLELED Evidence

Demonstrated Durable Relief at 5 Years⁹

Mean ODI Over Time

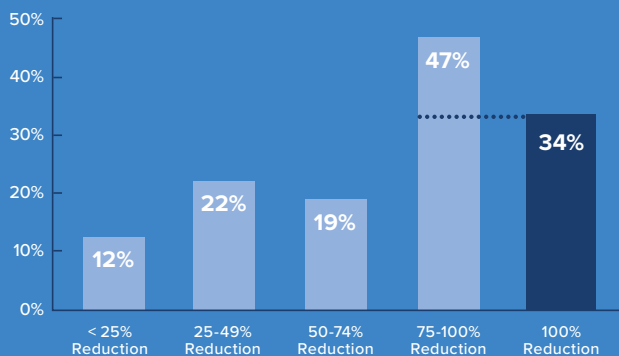


Mean VAS Over Time



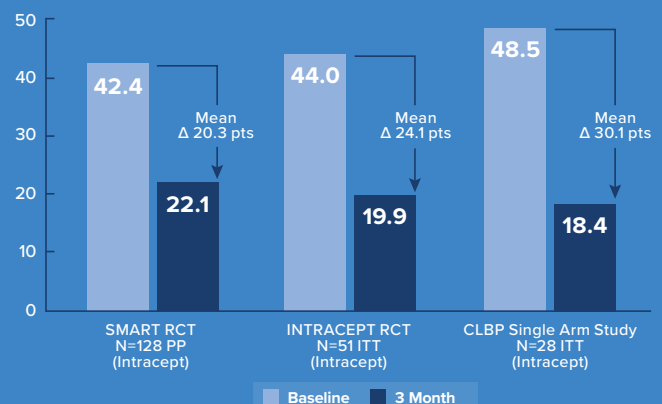
VAS Improvements⁹

Proportion of Patients by % VAS Reduction (Baseline to 5 Years)



Reproducible Outcomes^{10,11,12}

Improvement in ODI from Baseline to 3-Months



REFERENCES

1. Fields AJ, Liebenberg EC, Lotz JC. Innervation of pathologies in the lumbar vertebral endplate and intervertebral disc. *The Spine Journal: Official Journal of the North American Spine Society* 2014;14(3):513-521.
2. Bailey JF, Liebenberg E, Degmetich S, Lotz JC. Innervation patterns of PGP 9.5-positive nerve fibers within the human lumbar vertebra. *Journal of Anatomy* 2011;218(3):263-70.
3. Lotz JC, Fields AJ, Liebenberg EC. The Role of the Vertebral End Plate in Low Back Pain. *Global Spine J* 2013;03:153-64.
4. Modic MT, Steinberg PM, Ross JS, Masaryk TJ, Carter JR. Degenerative disk disease: assessment of changes in vertebral body marrow with MR imaging. *Radiology* 1988;166:193-9.
5. Carragee EJ, Alamin TF, Miller JL, Carragee JM. Discographic, MRI and psychosocial determinants of low back pain disability and remission: a prospective study in subjects with benign persistent back pain. *The Spine Journal: Official Journal of the North American Spine Society* 2005;5(1):24-35.
6. Weishaupt D, Zanetti M, Hodler J, et al. Painful Lumbar Disk Derangement: Relevance of Endplate Abnormalities at MR Imaging. *Radiology* 2001;218(2):420-7.
7. Kuisma M, Karppinen J, Niinimäki J, et al. Modic changes in endplates of lumbar vertebral bodies: prevalence and association with low back and sciatic pain among middle-aged male workers. *Spine* 2007;32(10):1116-22.
8. Mok K, Samartzis D, Karppinen J, et al. Modic changes of the lumbar spine: prevalence, risk factors, and association with disc degeneration and low back pain in a large-scale population-based cohort. *The Spine Journal: Official Journal of the North American Spine Society* 2016;16(1):32-41.
9. Fischgrund JS, Rhyne A, Macadaeg K, Moore G, Kamrava E, Yeung C, et al. Long-term outcomes following intraosseous basivertebral nerve ablation for the treatment of chronic low back pain: 5 year treatment arm results from a prospective randomized double-blind sham-controlled multi-center study. *Eur Spine J*. epub May 25, 2020. <https://doi.org/10.1007/s00586-020-06448-x>
10. Fischgrund JS, Rhyne A, Franke J, et al. Intraosseous basivertebral nerve ablation for the treatment of chronic low back pain: a prospective randomized double-blind sham-controlled multi-center study. *European Spine Journal*. 2018;27(5):1146-1156. doi:10.1007/s00586-018-5496-1
11. Khalil J, Smuck M, Koreckij T, et al. A Prospective, Randomized, Multi-Center Study of Intraosseous Basivertebral Nerve Ablation for the Treatment of Chronic Low Back Pain. *The Spine Journal* 2019; doi: <https://doi.org/10.1016/j.spinee.2019.05.598>
Assume INTRACEPT pub has the 3 month in graph above
12. Truumees, E., Macadaeg, K., Pena, E. et al., A prospective, open-label, single-arm, multi-center study of intraosseous basivertebral nerve ablation for the treatment of chronic low back pain *Eur Spine J* (2019). doi.org/10.1007/s00586-019-05995-2



Relievent Medsystems, Inc.

8500 Normandale Lake Blvd, Suite 2150
Minneapolis, MN 55437
P 650-368-1000
relievent.com